

A Single Tooth Restoration With ELEMENT in a Challenging Esthetic Situation



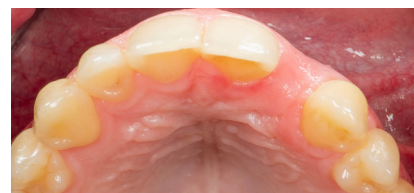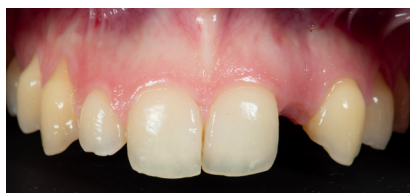Dr. Alfonso Gil,
Spain
www.clinicadentalalbia.com



The Baseline Situation

A patient with a congenitally missing lateral 22

A female patient presented with a congenitally missing lateral 22. She had been wearing a resin bonded bridge for more than 10 years with multiple decementations and asked for a fixed implant solution. The missing tooth gap was very narrow and the soft tissue volume was deficient in site 22.



The Treatment Strategy

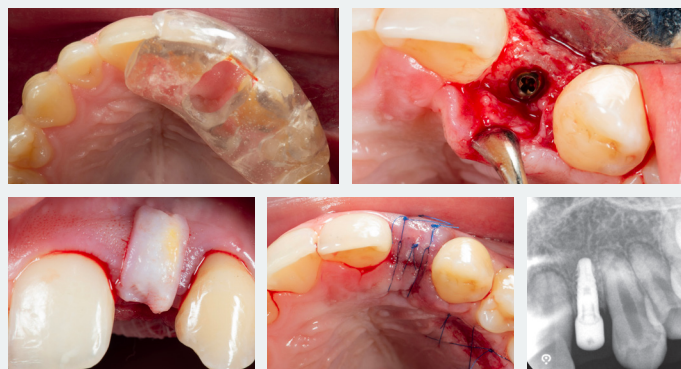


1 Implant surgery

Implant surgery following a semi-guided approach, with the use of a conventional surgical guide

Placement of an ELEMENT INICELL® (PF 3.0) implant at a screw retained position with enough bone on the buccal side

Harvesting of a connective tissue graft and placement on the buccal side of the implant

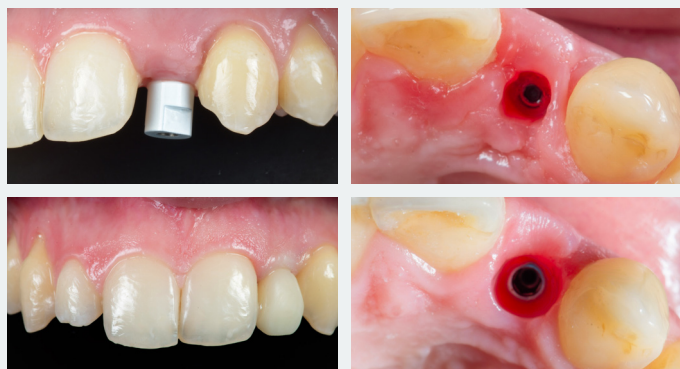

2 Prosthetic restoration

Performance of a digital workflow for the fabrication of the implant restorations

Digital impression of the implant performed in order to first fabricate a provisional restoration to develop the emergence profile

Creation of the definitive veneered zirconia restoration, once the emergence profile was of ideal dimensions



The Outcome

The final restoration blends with the patient's own dentition and is esthetically and functionally pleasing. Both the soft tissue and the marginal bone levels are healthy and stable at the final visit

