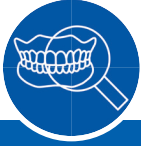

# Case Report Series

## Rehabilitation of a Single Molar Tooth With Immediate Implant Placement



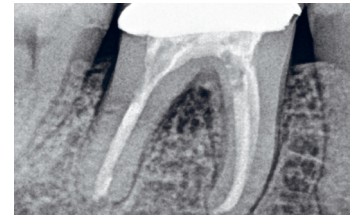
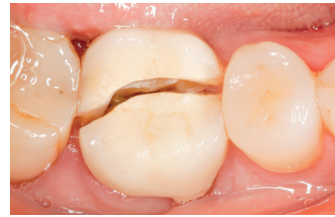Dr. Jevgenij Travkin,  
Lithuania



### The Baseline Situation

#### Patient with cracked lower molar tooth

A female patient sought treatment at the dental clinic due to a cracked lower molar tooth 46, which was causing her significant pain and mobility issues.

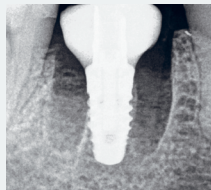
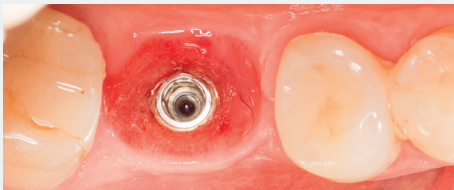


### The Treatment Strategy



#### 1. Surgery

#### 2. Final prosthetic restoration

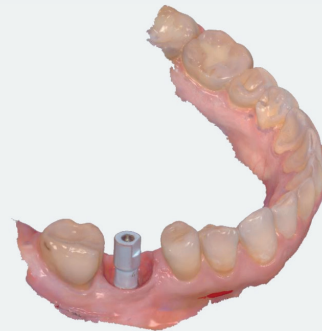

Performed under local anesthesia

Immediate extraction of tooth 46, Immediate placement of an ELEMENT MC INICELL® implant (PF 4.0, L 8.0 mm), torque value 35 Ncm

No use of grafting material

Use of temporary customizable abutment (VARIOtemp & composite)



Final restoration after successful osseointegration, utilizing a fully digital workflow

Fixation of screw-retained zirconia, full monolithic restorations



### The Outcome

Following one-year post-treatment, the patient exhibits stable bone and tissue levels. The streamlined treatment approach minimized the number of appointments, contributing to high patient satisfaction. The patient is pleased with the final esthetics

