



# Case Report Series

## Immediate Implant Placement With NEVO in the Posterior Region



Dr. Alfonso Gil,  
Spain

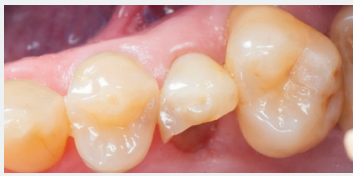[www.clinicadentalalbia.com](http://www.clinicadentalalbia.com)

"I particularly appreciate the strong clinical grip and precise handling during NEVO implant placement"



### The Baseline Situation

Patient with a fractured premolar



A 48-year-old patient presented at the practice with a fractured premolar in the maxilla, seeking a reliable, fixed solution through implant treatment.

### The Treatment Strategy



#### 1 Immediate implant placement & grafting

Extraction of tooth in multiple pieces

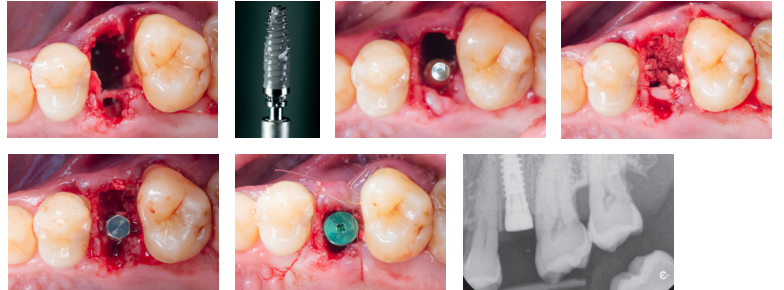
Identification of a missing buccal plate [dehiscence] of 4 mm

Placement of a NEVO RC INICELL® implant (PF 4.0, L 12.5 mm) in an ideal prosthetic position, carefully avoiding the sinus (Insertion torque: 30 Ncm)

Grafting of the buccal gap with a bovine bone substitute (Bio Oss granulates)

Placement of a small resorbable collagen membrane, followed by suturing on the buccal side with PGA 6-0s sutures

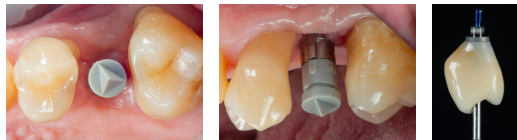
Transcrestal healing with healing abutment



#### 2 Intraoral scanning

Intraoral scanning with primescan

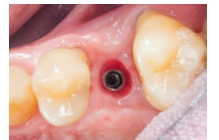Inhouse fabrication of a veneered lithium disilicate crown cemented on a ti-base



#### 3 Crown delivery

Delivery of the screw-retained restoration

Closure of the screw channel with composite



### The Outcome

The implant healed successfully, and within only three appointments, it was fully restored. The patient is pleased with the esthetic results, and clinical examination shows healthy bone and tissue levels.

