



Case Report Series

Successful Rehabilitation of a Fractured Molar Tooth with NEVO



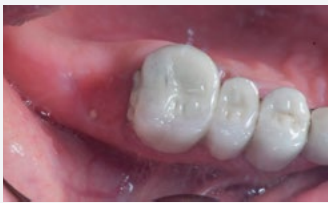Dr. Alfonso Gil, Spain
www.clinicadentalalbia.com

“What stood out to me about NEVO was the excellent clinical grip and ease of handling during placement”



The Baseline Situation

Referred patient for implant placement of missing tooth 27



A 60-year-old female patient was referred for implant placement after the extraction of fractured tooth 27. Molar 27 had fractured while part of an existing bridge and was extracted by the previous dentist. The patient was referred for the implant surgery and fabrication of the crown.

The Treatment Strategy



1 Implant placement

Freehand placement of a NEVO RC INICELL® implant (PF 4.0, L 8.0 mm), using the adjacent tooth and opposing dentition as reference (Insertion torque: 30 Ncm)

Placement of healing abutment

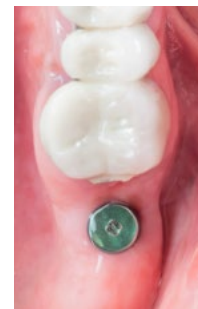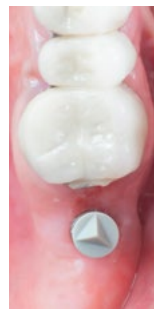
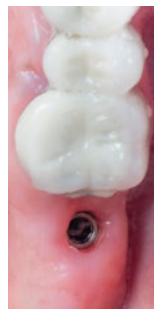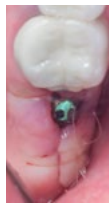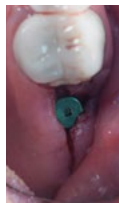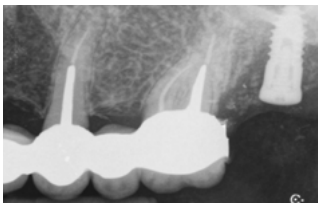

2 Digital impression

Digital impression taken 6 weeks post-implant placement using a Primescan IOS

3 Crown delivery

In-house fabrication of the crown with a CEREC milling machine (CEREC inlab Mc XL) in monolithic lithium disilicate

Cementing of crown on a Titanium Base



The Outcome

With just three appointments, the case was successfully completed. Radiographs confirmed stable bone levels, the soft tissue appeared healthy, and the patient was very satisfied with the result

