



# Case Report Series

## Immediate NEVO Implant Placement for a Single Tooth in the Molar Area



Dr. Mathieu Rousset, France

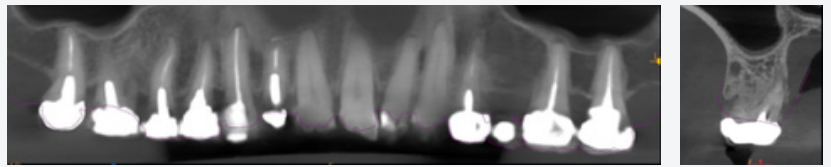
“What I appreciate about NEVO are the ease of insertion, the stability and the possibility to modify the axis during the insertion”



### The Baseline Situation

#### Patient needing rehabilitation of tooth 16

A 58-year-old female patient presented at the dental office with a previously root-canal treated upper molar 16 that required extraction. She sought a fixed rehabilitation solution using implants.



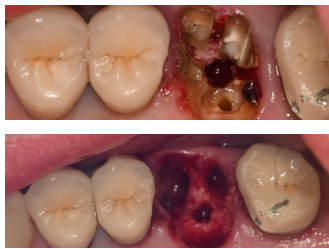### The Treatment Strategy



#### 1 Tooth extraction

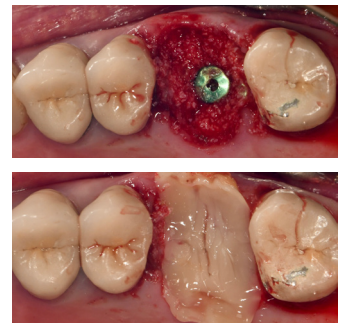
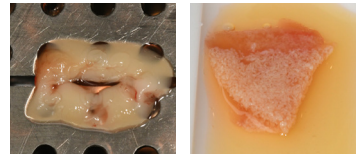
Sectioning of the root

Drilling into the root to facilitate tooth extraction



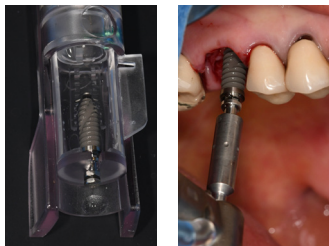#### 3 Bone regeneration

Regeneration of bone with PRF membrane and “sticky bone”



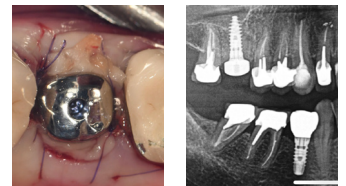
#### 2 Implant placement

Free-hand placement of a NEVO RC INICELL® implant without prior drilling



#### 4 Instertion of healing cap

Placement of a physiological healing cap



### The Outcome

The post-operative period was uneventful. Three months after the surgery, the soft tissue around the implant appears very healthy. X-ray images show stable bone levels around the implant.

