




Case Report Series

Guided Immediate Placement of NEVO Implants for a Bridge in the Esthetic Zone



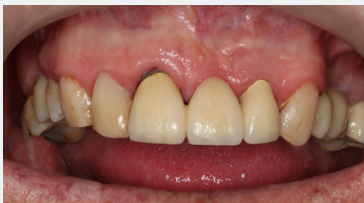Dr. Stijn Kregting
Netherlands

“With NEVO, I have more confidence in having a high primary stability in challenging clinical scenarios”



The Baseline Situation

Patient with a loose bridge on teeth 11-22



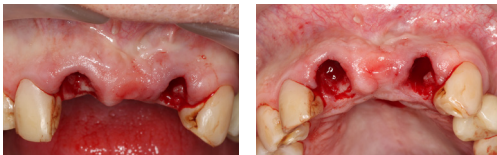A patient with a 30-year-old dental bridge on teeth 11-22 presented after the bridge had come loose for approximately the tenth time. Examination revealed secondary caries and a small apical granuloma on tooth 22.

The Treatment Strategy



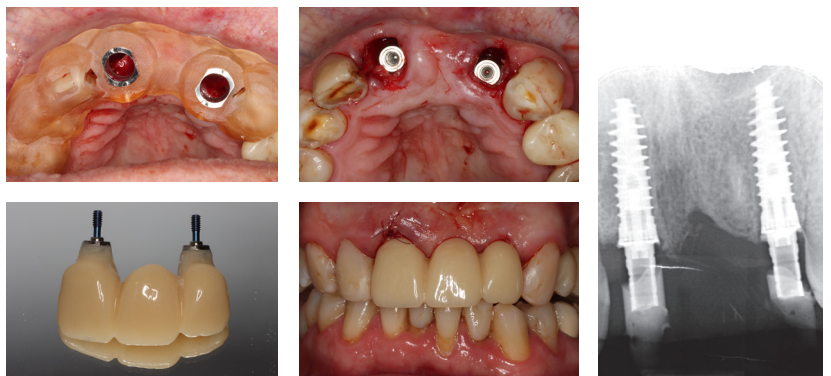
1 Tooth extraction

Atraumatic extraction of teeth 11 and 22
Removal of granuloma and endo cement debris



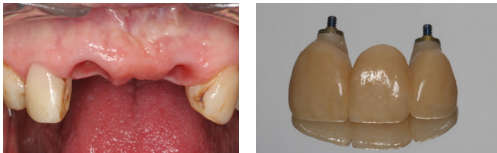2 Immediate implant placement & provisional

Fully guided drilling and placement of two NEVO RC INICELL® implants (PF 4.0, L 12.5 mm) directly into extraction socket
Capturing of the temporary with primer and flowable composite
Filling up of the buccal gap with “sticky bone” and PRF
Placement of temporary bridge with 20 Ncm



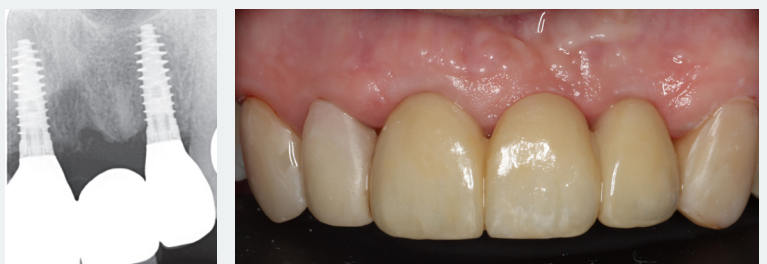3 Final restoration

Placement of screw-retained final restoration after 5 months of uneventful healing



The Outcome

After the final restoration, the patient was very pleased with the esthetic outcome. The adjacent tissue looks healthy, and X-rays show stable bone levels.



L, length; Ncm, newton centimeter; PF, platform; PRF, platelet-rich fibrin; RC, regular collar.