




# Case Report Series

## Immediate Implantation With NEVO on Tooth 36



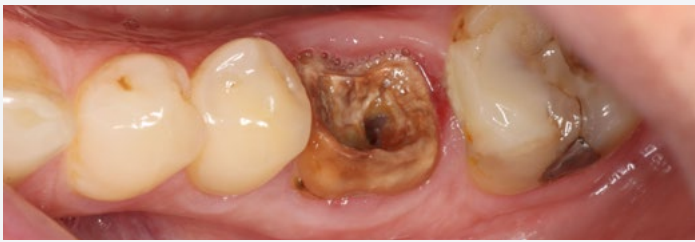Dr. Stijn Kregting,  
Netherlands

“With NEVO, I have more confidence in having a high primary stability in challenging clinical scenarios”



### The Baseline Situation

Patient with loose crown on tooth 36



A patient presented with a lost crown on tooth 36, which revealed underlying secondary caries.

### The Treatment Strategy



#### 1 Tooth extraction

Atraumatic extraction of tooth 36

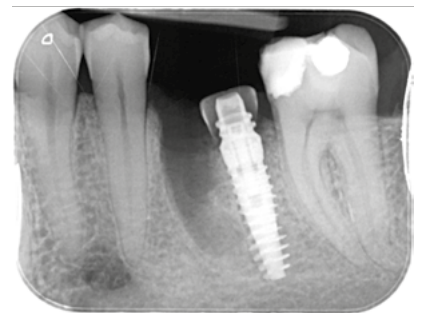
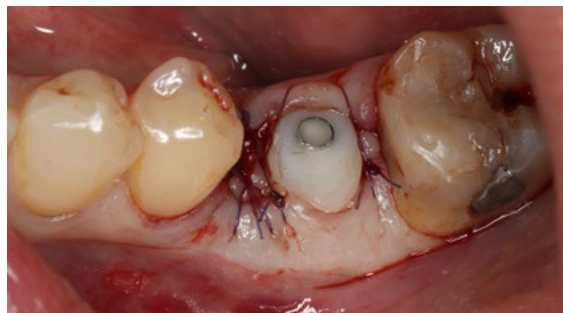
#### 2 Immediate implant placement

Freehand drilling and distal placement of a NEVO RC INICELL® implant (PF 4.0, L 12.5 mm) directly into extraction socket

Making of a temporary abutment with PMMA and flowable composite

Filling up of the mesial root socket with PRF

Placement of temporary abutments with 15 Ncm



### The Outcome

Following the placement of the final restoration, the patient was very satisfied with the result. The surrounding tissue appeared healthy, and radiographic examination confirmed stable bone levels, indicating a successful outcome

