




# Case Report Series

## Immediate Fully Guided Implantation of NEVO in the Esthetic Zone



Dr. Stijn Kregting,  
Netherlands

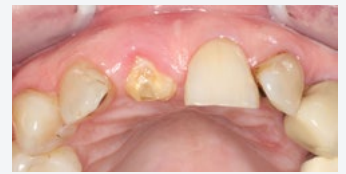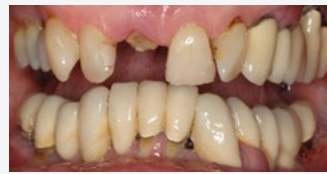“With NEVO, I have more confidence in having a high primary stability in challenging clinical scenarios”



### The Baseline Situation

Patient with lost crown on tooth 11

A patient presented with a lost crown, including the buildup, on a central incisor. Restoration was deemed not advisable.

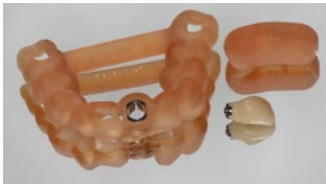

### The Treatment Strategy



#### 1 Planning

Fully guided planning



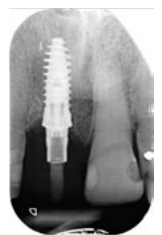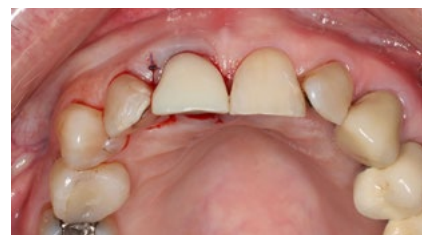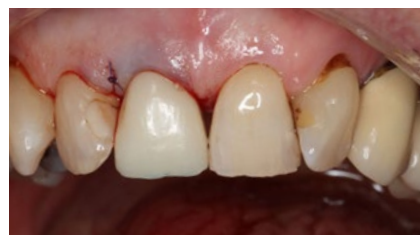#### 2 Tooth extraction & immediate implantation

Atraumatic extraction of tooth 11

Fully guided drilling and placement of a NEVO RC INICELL® implant (PF 4.0, L 11.0 mm) directly into extraction socket

Placement of bone substitute (Gen-oss) with PRF into socket

Placement of temporary restoration with 25 Ncm



### The Outcome

Three months post-surgery, a full zirconium crown was placed. The patient was highly satisfied with the outcome, as the surrounding tissue looked healthy and radiographs showed stable bone levels, confirming the success of the treatment

