



Case Report Series

Rehabilitation of a Lower Molar Tooth With NEVO in a Healed Site



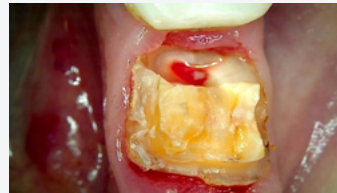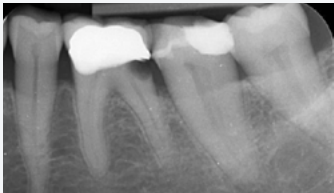
Dr. Christian Ramel,
Switzerland

“NEVO implants offer a seamless insertion experience, instilling confidence even in standard situations. Their convincing performance in challenging as well as standard cases encourages me to consider exclusively using NEVO implants, simplifying my inventory and ensuring readiness for all types of cases.”



The Baseline Situation

Patient with profound caries on a lower molar tooth



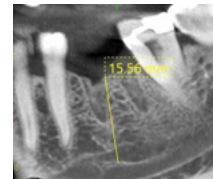
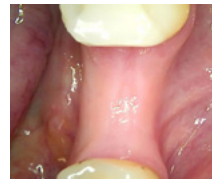A 65-year-old female patient presented with tooth loss due to profound caries. Extraction was opted for, as root canal treatment, crown lengthening, and a new crown would have incurred costs nearly equivalent to those of an implant.

The Treatment Strategy



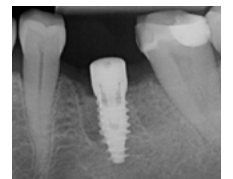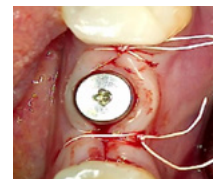
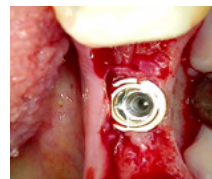
1 Tooth extraction

Extraction of tooth
3 months of uneventful healing



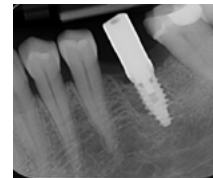
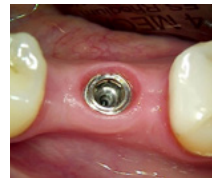2 Implant placement after healing phase

Placement of NEVO RC INICELL® (PF 5.0, L 9.5) into healed ridge



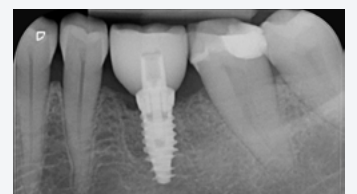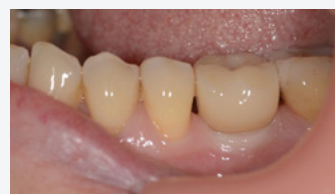3 Final restoration after 2 months

Taking of final impression 2 months after implant placement
Crown made of Lithium Disilicate and Zirconia on a Tibase



The Outcome

This case led to a successful restoration of function in the molar region. The soft tissue healed well with healthy contours around the implant, and radiographs confirmed stable bone levels. The patient was very satisfied with the final result.



L, length; PF, platform; RC, regular collar; Tibase, titanium base.