



Case Report Series

Immediate Placement of Two NEVO Implants for a Three-Unit Partial Denture in the Maxilla



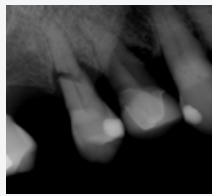
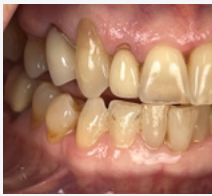Dr. Samantha Rawdin, US

“NEVO offers the trusted quality I have come to expect from Thommen Medical, giving me the confidence to apply it in new treatment approaches”



The Baseline Situation

Patient with horizontal root fractures on teeth 14 and 15



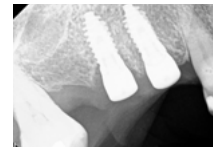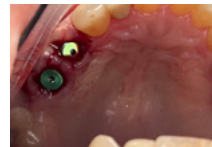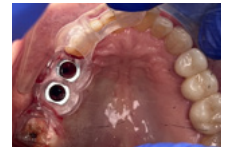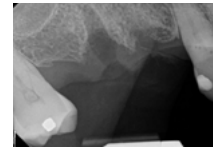
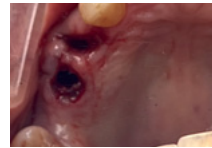A 79-year-old female patient with no significant medical history, except for taking Nexium for heartburn, presented with pain in the upper right maxillary region. Teeth 14 and 15 exhibited horizontal root fractures and were deemed non-restorable.

The Treatment Strategy



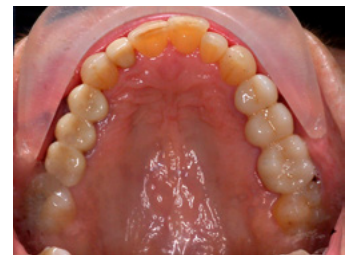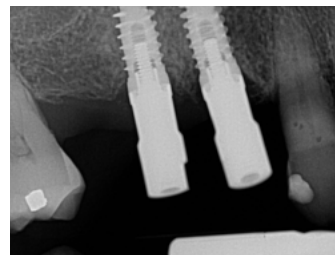
1 Teeth extraction & immediate NEVO placement

- Administration of 2g of Amoxicillin as prophylaxis prior to surgery
- Atraumatic extraction of both teeth
- Thorough curettage of extraction sockets to ensure removal of all granulatous tissue
- Placement of two NEVO RC INICELL® implants (PF 4.0, L 9.5 mm) regio 14 and 15 using a surgical guide
- Implants were placed with good primary stability at 45 Ncm
- Healing abutments were placed on both implants to facilitate soft tissue healing



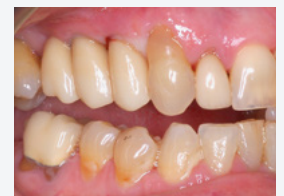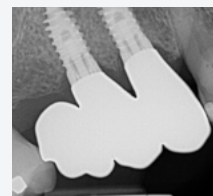2 Prosthetic Phase

- Healing for 12 weeks before final restoration planning
- Taking of a digital scan for a three-unit zirconia fixed partial denture (FPD) from 13 to 15, with a distal cantilever at site 16. The cantilevered segment was designed to be out of occlusion during maximum intercuspation and excursive movements
- Fabrication and delivery of the FPD on the day of the scan to accommodate the patient's long-distance travel to the clinic



The Outcome

The treatment was completed successfully with excellent clinical results. The implants integrated well, showing stable bone levels and healthy soft tissue. The patient was very satisfied with the final outcome, and the distal cantilever FPD functioned effectively with no occlusal interference. Healing was uneventful, and the restoration provided both functional and esthetic improvement.



FPD, fixed partial denture; L, length; Ncm, newton centimeter; PF, platform; RC, regular collar.